

Has This Prepubertal Girl Been Sexually Abused?

Molly Curtin Berkoff, MD, MPH

Adam J. Zolotor, MD, MPH

Kathi L. Makoroff, MD

Jonathan D. Thackeray, MD

Robert A. Shapiro, MD

Desmond K. Runyan, MD, DrPH

CLINICAL SCENARIOS

Case 1

A 6-year-old girl is brought to the emergency department by her mother. The mother states her child said a male babysitter “touched her” in the genital area. The mother reported the case to the police and was advised to bring the child to the emergency department for a medical examination. No behavioral problems were reported. The emergency department nurse asked the child why she thought her mother brought her to the hospital, and the child reported because of “what happened” with the babysitter. No further details were obtained. On physical examination she is sexual maturity rating 1. You note mild erythema of the inner aspect of the labia minora. The hymen is well visualized and appears normal. There is no bleeding, discharge, or lesions seen around the genitalia or anus. There are no other concerning examination findings. Is the lack of findings reassuring?

See also 2796.



CME available online at www.jamaarchivescme.com and questions on p 2807.

Context The legal and social sequelae of interpreting genital findings as indicative of sexual abuse are significant. While the absence of genital trauma does not rule out sexual abuse, the physical examination can identify genital findings compatible with sexual abuse.

Objectives To determine the diagnostic utility of the genital examination in prepubertal girls for identifying nonacute sexual abuse.

Data Sources Published articles (1966-October 2008) that appeared in the MEDLINE database and were indexed under the search terms of *child abuse*, *sexual* or *child abuse* and either *physical examination*; *genitalia*; *female*, *diagnosis*; or *sensitivity and specificity*; and bibliographies of retrieved articles and textbooks.

Study Selection Three of the authors independently reviewed titles of articles obtained from MEDLINE and selected articles for full-text review.

Data Extraction Two authors independently abstracted data to calculate sensitivity, specificity, and likelihood ratios for the diagnosis of nonacute genital trauma caused by sexual abuse in prepubertal girls.

Results Data were not pooled due to study heterogeneity. The presence of vaginal discharge (positive likelihood ratio, 2.7; 95% confidence interval, 1.2-6.0) indicates an increased likelihood of sexual abuse. In the posterior hymen, hymenal transections, deep notches, and perforations prompt concerns for genital trauma from sexual abuse, but the sensitivity is unknown. Without a history of genital trauma from sexual abuse, the majority of prepubertal girls will not have a hymenal transection (specificity close to 100%).

Conclusions Vaginal discharge as well as posterior hymenal transections, deep notches, and perforations raise the suspicion for sexual abuse in a prepubertal girl, but the findings do not independently confirm the diagnosis. Given the broad 95% confidence intervals around the likelihood ratios for the presence of findings along with the low or unknown sensitivity of all physical examination findings evaluated, the physical examination cannot independently confirm or exclude nonacute sexual abuse as the cause of genital trauma in prepubertal girls.

JAMA. 2008;300(23):2779-2792

www.jama.com

Case 2

An 18-month-old girl is brought to her pediatrician's office. Her family has noted blood in her diaper 1 week prior to the appointment. There is no history of trauma and no known explanation for the bleeding. On physical examination the child is crying but is easily calmed by her mother after the examination. The only significant finding is a separation or interruption (pos-

Author Affiliations: Division of General Pediatrics (Drs Berkoff and Runyan) and Department of Family Medicine (Dr Zolotor), University of North Carolina, Chapel Hill; Center for Safe and Healthy Children, Cincinnati Children's Hospital Medical Center, Cincinnati, Ohio (Drs Makoroff and Shapiro); and Center for Child and Family Advocacy, Nationwide Children's Hospital, Columbus, Ohio (Dr Thackeray).

Corresponding Author: Molly Curtin Berkoff, MD, MPH, Division of General Pediatrics, University of North Carolina, 231 MacNider, CB #7225, Chapel Hill, NC 27599 (molly_berkoff@med.unc.edu).

The Rational Clinical Examination Section Editors: David L. Simel, MD, MHS, Durham Veterans Affairs Medical Center and Duke University Medical Center, Durham, NC; Drummond Rennie, MD, Deputy Editor, JAMA.

Box 1. Suggested Behavioral Questions¹⁹

Does your child have difficulty with the following symptoms?

- Headaches
- Stomachaches
- Sleeping (falling asleep, staying asleep, nightmares)
- Appetite
- School performance
- Anger or aggression
- Sexualized behaviors (this can include masturbating frequently, acting out sexually with their peers, touching other people's genitalia, showing their own genitalia)
- Unusual fears
- Depression (such as crying easily)
- Unusual behaviors
- Changes in bowel or bladder habits

sible transection) of the posterior hymen that appears to extend to the base of the hymen. The source of the bleeding is not apparent. What is the chance that this is a normal finding?

WHY PERFORM A PHYSICAL EXAMINATION FOR SEXUAL ABUSE ACUTELY?

In 2005, more than 80 000 children in the United States were sexually abused and their cases were confirmed (substantiated) by child protective services.¹ This number likely underestimates the problem because it includes only incidents of sexual abuse brought to the attention of a mandated reporter, those determined to have enough evidence for substantiation, and because most states only include abuse by caregivers. A population survey of North Carolina and South Carolina mothers suggests that official statistics may grossly underestimate the true incidence.² In this computer-assisted, anonymous, telephone survey of 1435 mothers, while no mother reported her child had been forced to have sex with an adult or older child in the previous year, the prevalence

throughout childhood was 11/1000 (1.1%). Within the year prior to the survey, the same frequency (1.1%) of children had been touched in a sexual way or had been made to touch an adult or an older child. These results were similar to those obtained in a Gallup poll of child discipline and thus serve as an anchor for estimating the pretest probability (1%) that a child has been sexually abused.³ However, it is important to note that some surveys of adult women indicate a history of sexual abuse approaching 25%.⁴

The evaluation of children for sexual abuse involves a careful and time-consuming assessment. Each case requires a thorough history with particular attention to recent behavioral problems and a complete physical examination. Families may present with concerns that need immediate evaluation or concerns for sexual abuse may arise during an examination for a seemingly unrelated issue. However, for complicated cases it may be useful to identify the local or regional child abuse specialist; in 2009, the first child abuse pediatrics specialty examination is to be administered by the American Board of Pediatrics.

Among children who recently have been sexually abused (≤ 72 hours) and have had forensic evidence collected, up to 25% may have evidence of acute anogenital injury.⁵ A referral for an immediate examination should be made when (1) there is the possibility of acute trauma, (2) the child needs an evaluation for a symptom or illness, (3) emergency prophylaxis against infection is indicated, or (4) forensic evidence must be collected, typically within 72 hours of an acute event of sexual abuse.⁶

When looking at the prevalence of significant physical findings in non-acute examinations, case-series reports note that 95% of children with a history of sexual abuse will have unremarkable physical examinations.^{7,8} For some children, sexual abuse may not have involved complete penetration; for example, it may have only involved fondling or genital-genital contact. Furthermore, many children do not disclose a history of sexual abuse until long

after the abuse; the hymen and surrounding tissues heal rapidly, often leaving no signs of healed trauma.⁹⁻¹² Finally, penetration may have occurred without causing physical injury.

The legal and social sequelae of interpreting a physical examination finding as indicative or suggestive of sexual abuse are significant. Children with findings indicating sexual abuse may be removed from their family, the suspected abuser may be incarcerated, and/or the children may be stigmatized by their family and community. Therefore, it is extremely important that the examiner correctly identify abnormalities on the physical examination and relay the interpretation of these findings as well as their significance to the appropriate authorities (department of social services or child protection services, law enforcement, and clinicians).

Correctly interpreting the significance of a normal examination in the presence of a history of sexual abuse also is important. A completely normal examination does not exclude abuse and is the most frequent examination finding in children who have been sexually abused.^{7,8,13,14} Sexually abused children with an unremarkable physical examination may be left to suffer ongoing abuse or judged to be lying if the normal examination is incorrectly interpreted as having ruled out sexual abuse. The misinterpretation of examination findings may have significant consequences for the child's mental health, relationships with family and friends, and protection against ongoing abuse.

Recent publications describe the necessary components of a sexual abuse evaluation in children and recommend an approach to interpreting physical findings in suspected child sexual abuse.^{6,15,16} These guidelines suggest there are few nonacute physical examination findings that support a disclosure of child sexual abuse. However, the diagnostic utility of these nonacute findings is not well described. We conducted a systematic review of the literature on the diagnostic utility of nonacute physical examination findings for identifying sexual abuse in prepubertal girls.

Our review focused solely on genital findings; it did not include anal or oral findings or review the precision and accuracy of history or laboratory tests (such as tests for sexually transmitted infections [STIs] or seminal fluid).

Taking a History

A clinician may have concerns from the clinical history that a child has been sexually abused. Clinicians who care for children must have a strategy for approaching both the patient and adults accompanying the child. When obtaining a history for possible child sexual abuse, the clinician should attempt to interview the caregiver and the child separately. This is especially important if the caregiver reports the child has made a disclosure of sexual abuse

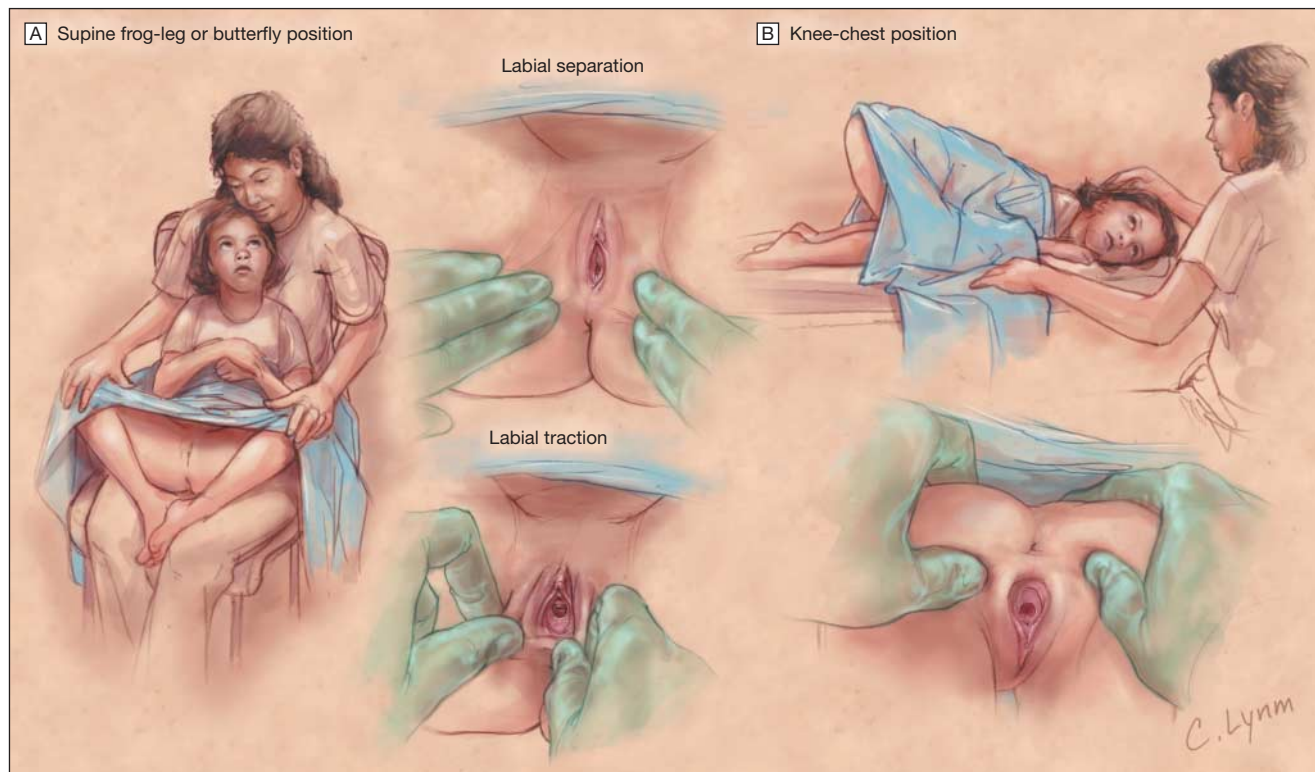
and/or assault. The focus should be a brief assessment with good documentation, which should include quotes of what was said.

For examiners not skilled with the interviewing of young children, a limited set of questions should be used including open-ended questions (such as "Tell me more" or "I understand someone is worried about you, can you tell me about that"). The examiner should avoid the use of yes or no questions.^{6,17} Extended interviews of children younger than 3 years are not likely to be useful. Care should be made to avoid multiple interviews by different medical personnel. Consideration should be made to refer a child for an interview by a professional experienced in the evaluation of child sexual abuse. Further specifics of

the interview of young children are detailed in experts' recommendations.¹⁸

The caregiver should be asked to describe the context of the child's disclosure, including if the disclosure was spontaneous or was facilitated by the caregiver. As with any medical history, a complete history and review of systems should be included. The history should include questions focusing on any new behavioral symptoms and any new medical symptoms of the child, including questions about genitourinary and gastrointestinal tract symptoms. Suggested behavioral questions are listed in BOX 1. These questions are not meant to be used as a general screening for child sexual abuse. Instead, they are questions that may assist with formulating a review of systems when con-

Figure 1. Positions and Techniques for Examination of Genitalia in Prepubertal Girls



Two examination positions commonly used are the supine frog-leg or butterfly position and the knee-chest position. When findings are abnormal or concerning in the supine position, the examination should be repeated in the knee-chest position to provide additional certainty or clarification. The knee-chest position provides greater visibility of genital structures because gravity may unfold the hymenal tissue. The positions in which findings are observed should be recorded. A, In supine position, the child is examined supine on the examination table or alternatively, sitting on the lap of a trusted adult. Labial separation (performed first) helps the examiner get an initial view of the genital structures. Labial traction permits a complete view of the genital structures. B, To view the genital structures in the knee-chest position, the examiner holds the buttocks apart by pressing laterally and upward.

cerns of child sexual abuse have been raised. It is important to try to establish a history of onset for any positive responses because they may help formulate a differential diagnosis. A positive response should be explored to obtain details of symptoms and associated findings.

At present there are no screening tools for making a diagnosis of child sexual abuse. However, specific screenings ex-

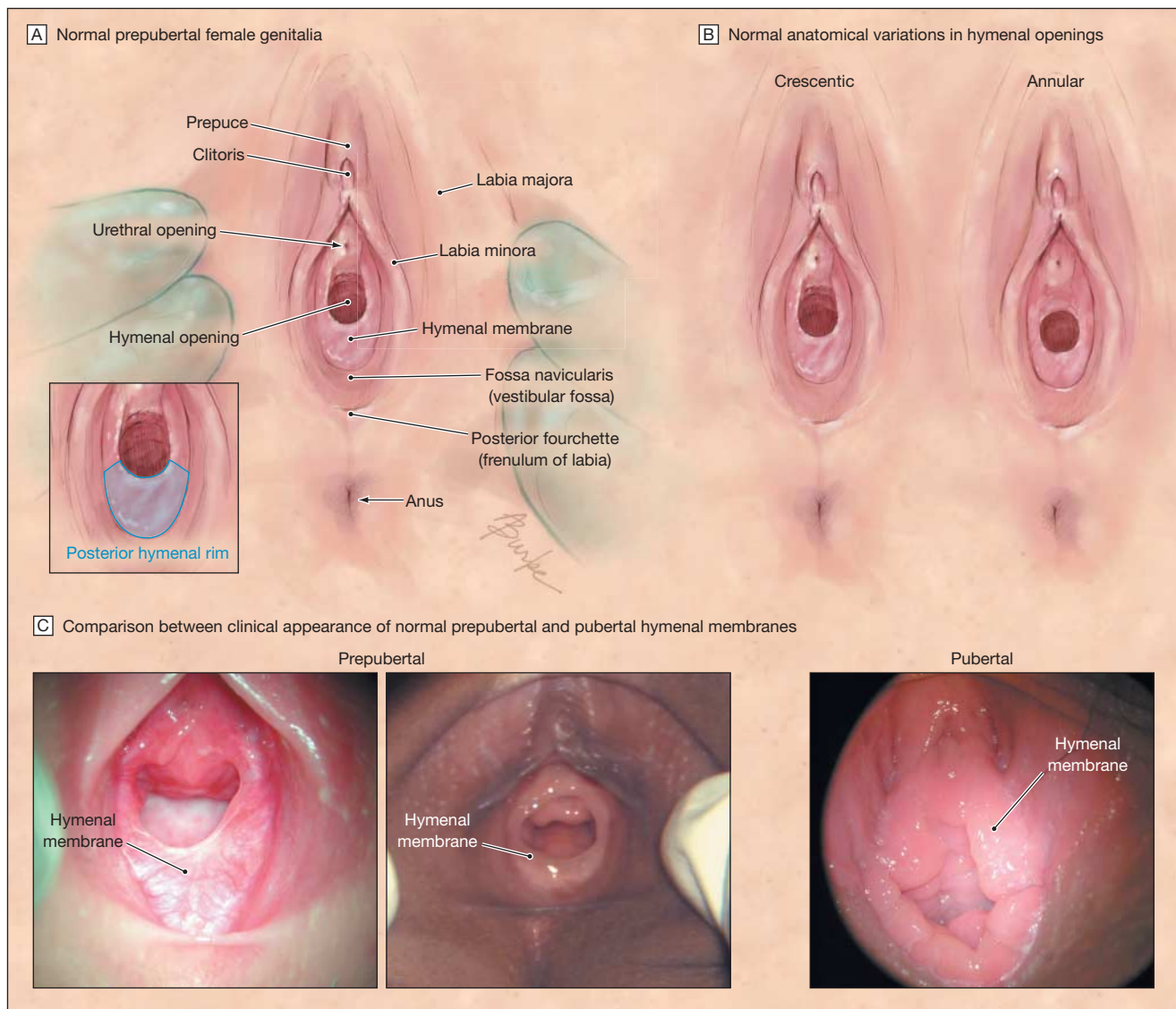
ist to assess children's sexualized behaviors, language skills, and unusual behaviors.²⁰ These specific screenings may be helpful to support a diagnosis of sexual abuse. While not typically recommended for use in the general patient population, they are tools that can be used by an examiner specifically trained in interviewing children. In the clinical setting of child sexual abuse diagnosis, the screenings augment the informa-

tion obtained from the caregiver interview (including an exploration of behavioral problems), child interview, and the physical examination of the child.^{6,20}

Performing a Physical Examination

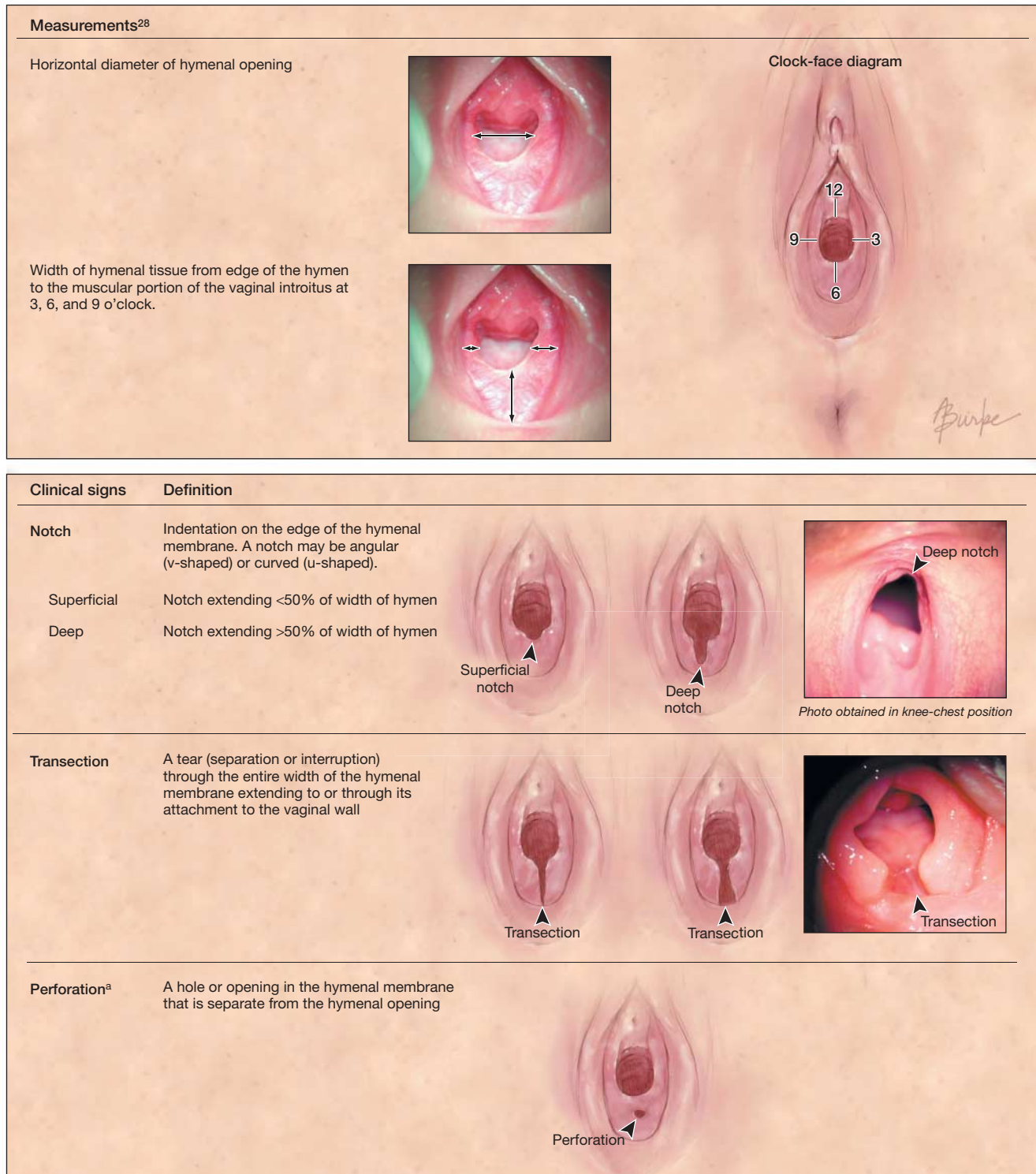
A complete physical examination is encouraged for many reasons. Sexual abuse may involve oral penetration or trauma in addition to genital and anal contact. Because a child who is sexually abused

Figure 2. Female Prepubertal Genital Anatomy



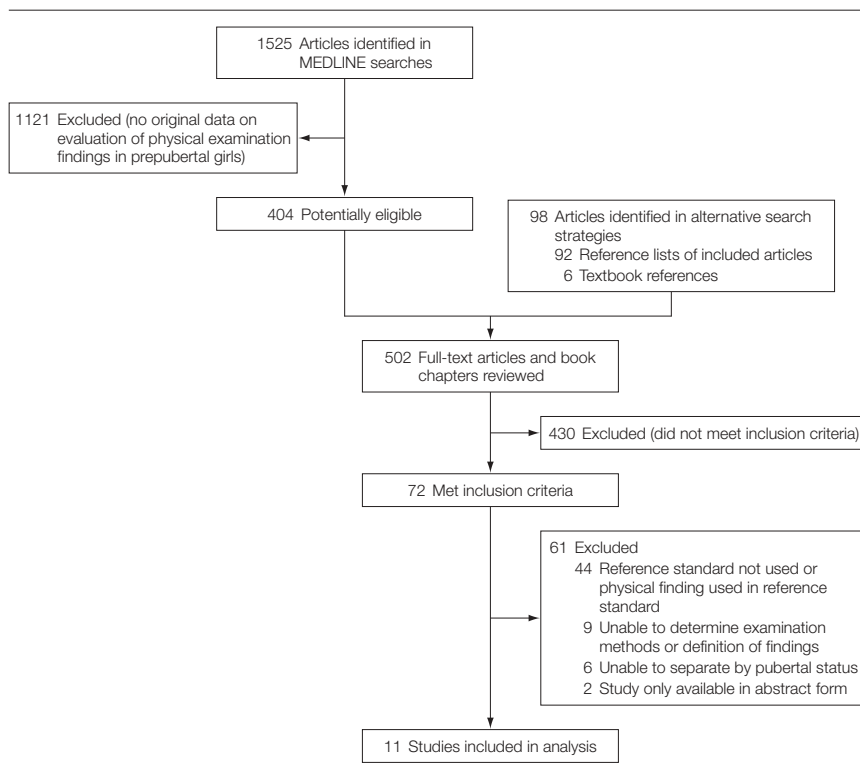
A, Inset, The region defined as the posterior hymenal rim, between 4 and 8 o'clock, is shaded blue. B, There is a range of normal anatomical variations in hymenal openings. Crescentic and annular are 2 of the most common shapes. C, The photographs illustrate the range of normal prepubertal hymenal membranes. In most children, the hymen becomes thicker and more redundant during puberty.

Figure 3. Hymenal Membrane Characteristics



When considering the possibility of sexual abuse during an examination, the examiner should document pertinent positive and negative findings. In addition to the clinical signs depicted in the figure, other possible findings include prominent hymenal vessels, bumps, tags, longitudinal intravaginal ridge, external ridge, periurethral bands, or vestibular bands.

^aPerforation is a finding reported from Berenson et al.²⁸ Perforation of the hymen is not a finding commonly discussed in the literature.

Figure 4. Study Selection Process

also may experience other forms of trauma such as physical abuse and neglect, a complete physical examination may reveal bite marks, burns, bruises, or patterned injuries. Studies have suggested that children who experience maltreatment may have unmet medical needs such as untreated dental caries,²¹ which will be recognized only after a complete physical examination. A complete physical examination also helps to deemphasize the genital examination, which may be an awkward examination for the child. Finally, a genital examination may be viewed by some children as therapeutic.²²

Examination Positions

There are 2 examination positions commonly used in child sexual abuse. The first position is referred to as the supine, frog-leg or butterfly position (FIGURE 1A).

In this position, the child is asked to bend her knees and place the bottoms of her feet together while abducting her legs. Neither a speculum nor stirrups are

used in the prepubertal female genital examination. The examiner should inspect the genitalia (FIGURE 2) for any signs of lesions, discharge, trauma (such as bruising), or scarring. The child's sexual maturity rating also should be noted.²³ To examine the hymen, the examiner separates the labia majora by applying traction. By gently grasping the labia bilaterally between the thumb and forefinger and then pulling gently outward and downward, the hymenal tissue and vaginal opening should be completely visualized without causing discomfort. If findings appear concerning or abnormal, the examination should be repeated in the knee-chest position (Figure 1B) to provide additional certainty to the findings noted in the standard, supine position. The knee-chest position permits far greater visibility of the vagina because gravity may unfold hymenal tissue to clarify concerning findings from the supine view.²⁴ The child kneels in a prone position on the examination table and places her head and chest onto the examination table.⁶

Many studies have demonstrated poor correlation in genital examination interpretation between experienced and inexperienced examiners.^{25,26} Inexperienced examiners should have abnormal findings confirmed by an experienced examiner. When possible, all genital findings should be photodocumented. Before photodocumenting, the examiner must be mindful of the specific allegations because child pornography is a form of child sexual abuse, which some children may have been experienced. Examiners performing photodocumentation for evidentiary purposes might need to obtain consent from caregivers and assent from children.

Testing for STIs

The US Centers for Disease Control and Prevention has guidelines for STI testing in cases of suspected sexual abuse, which include when to test for human immunodeficiency virus, hepatitis B and C, and syphilis.²⁷ In addition, the American Academy of Pediatrics has recommendations for when to test prepubertal children for STIs.⁶ When considering the diagnosis of sexual abuse, if vaginal discharge is present the evaluation should include tests for *Neisseria gonorrhoeae*, *Chlamydia trachomatis*, and *Trichomonas vaginalis* from the vagina and not the cervix because vaginal samples are adequate for STI testing in prepubertal girls.⁶ Infection in prepubertal girls causes vaginitis, not cervicitis. Specimens therefore are obtained from the vaginal vault or just proximal to the hymen. Avoiding direct contact with the hymenal tissue is important because this is an area very sensitive to touch in most prepubertal girls. Confirmatory testing is almost always indicated to exclude false-positive test results. Current studies are evaluating the characteristics of nucleic amplification tests in prepubertal girls, but cultures are considered the current criterion standard. Presumptive treatment for gonorrhea and chlamydia is not recommended for the prepubertal patient due to the low incidence in these patients, the low risk of ascending infection, and the frequent

need for confirmatory testing. Human immunodeficiency virus and hepatitis B prophylaxis, when indicated, are both exceptions to this recommendation.

The presence of an STI does not always mean a child was sexually abused. For some STIs, the clinician must carefully evaluate whether the child could have obtained these infections from a nonsexual mechanism such as acquisition at the time of birth or autoinoculation.⁶ Referral to or consultation with a child abuse specialist is highly recommended if an STI is diagnosed. A discussion of the interpretation of STIs is beyond the scope of this article.

Documentation of the Genital Examination

A complete description of findings should be noted, including the child's position during the examination and whether labial traction was used. Documentation should include a notation of the sexual maturity rating. Additional items to document include the presence of erythema, lesions, abrasions, bruising, lacerations, scarring, or discharge with reference to the anatomic location of each finding (Figure 2). Current convention uses a clock-face analogy to indicate locations of the hymen; 12 o'clock describes the area of the hymen closest to the urethra. The examiner should describe and document the hymenal characteristics and whether the hymenal edges contain irregularities such as notches, bumps, or complete transections (FIGURE 3). Significant findings and their location should be recorded. The examiner also should record pertinent negatives. If photos of the examination are obtained, this should be documented.

METHODS

Search Strategy

Articles in the MEDLINE database were identified using the PubMed search engine from 1966-October 2008. The Cochrane database did not contain relevant articles. There were 2 searches using different main Medical Subject Headings of *child abuse* (used from 1966-1987) and *child abuse, sexual*

(added beginning in 1987). These main Medical Subject Headings were combined with the following terms: *sensitivity and specificity*; *genitalia, female*; *physical examination*; and *diagnosis*. Both searches were limited to articles published in the English language and containing human participants. Together, the searches produced a total of 1525 articles (FIGURE 4).

Three of the authors (M.C.B., K.L.M., J.D.T.) reviewed the titles and available abstracts for the 1525 articles, selecting for further review the articles that appeared to address the evaluation of prepubertal girls for signs of sexual abuse and/or hymenal trauma. Articles were selected for full-text review if they included prepubertal girls (defined as ≤ 10 years if pubertal status not mentioned) and contained original research. When there was disagreement between the reviewers, the article was pulled for full-text review. Full-text review was performed by 2 of the authors (M.C.B., A.J.Z.). Reference sections of all 404 articles selected for full-text review were scanned for materials not available on PubMed and those not included in the original search. An additional 98 articles and book chapters were identified from the reference sections of the original articles. Thus, 502 articles and book chapters were considered.

To be included in this analysis, articles had to (1) contain data permitting calculation of test characteristics by pubertal status and/or age, (2) provide sufficient data for statistical analysis, (3) use a well described or reproducible examination technique, and (4) include a reference standard to determine whether a child had been sexually abused. Acceptable reference standards included information about the child's court disposition, perpetrator confession, substantiation by the department of social services or child protection services, or diagnosis by a community or hospital-based child protection team when physical findings were not used to determine level of suspicion of sexual abuse. When articles were limited to only children without a history of sexual abuse, inclusion cri-

Box 2. Criteria for Determining Quality Score

Level 1

Independent, blind comparison of physical examination findings with a reference standard among a large number of consecutive patients

Level 2

Independent, blind comparison of physical examination findings with a reference standard among a small number of consecutive patients

Level 3

Independent, blind comparison of physical examination findings with a reference standard among nonconsecutive patients

Level 4

Nonindependent comparison of the physical examination findings with a reference standard among nonconsecutive patients

teria needed to clearly outline reasons for how the authors excluded the possibility of sexual abuse. Eleven studies met all criteria and were included in this review. Information regarding quality score is included in BOX 2. A summary of these articles is presented in TABLE 1 and TABLE 2.

Statistical Analysis

Data were abstracted from the articles and entered into 2×2 tables to calculate the point estimates and 95% confidence intervals (CIs) for the likelihood ratios (LRs). When studies reported only the specificity, the 95% CIs for the specificity are shown with 0.5 added to the numerator and denominator when the specificity is 100% (rounded down to provide larger, more conservative 95% CIs). Test characteristics of all physical findings that would be easily recognized by a clinician who is not considered a specialist in child sexual abuse examinations are presented. Results were not mathematically pooled due to the varying methods and definitions used by each article. Instead, a range is reported where a summary value is warranted.

RESULTS

Eleven articles met the inclusion criteria. Only 2 of these articles included prepubertal girls with and without a history of sexual abuse,^{28,29} allowing us to calculate LRs. None of these articles included information allowing for the interpretation of physical examination findings acutely (≤ 72 hours of the event). The remaining 9 articles only included prepubertal girls without a history of sexual abuse, permitting estimation only of the specificity of the findings.

Diagnostic Value of Physical Examination Findings

Sensitivity, specificity, and positive and negative LRs derived from the 2 articles that included both populations of prepubertal girls are included in TABLE 3. The signs of vaginal discharge or the diameter of the hymenal opening were the only findings where the 95% CIs for both the positive and negative LRs excluded 1.0.

The presence of vaginal discharge (LR, 2.7; 95% CI, 1.2-6.0) or a diam-

eter of the hymenal opening of greater than 6.5 mm in the knee-chest position (LR, 2.0; 95% CI, 1.3-3.2) are the findings with the highest positive LRs for sexual abuse. Diagnostic characteristics of vaginal discharge were limited to the presence or absence of the finding. Diagnostic characteristics of the diameter of the hymenal opening included children examined in supine and knee-chest position with traction. Despite the higher positive LR for vaginal discharge, it is present in only 11% of prepubertal children with a history of sexual abuse. A diameter of the hymenal opening greater than 6.5 mm in the knee-chest position was present in 29% of prepubertal girls with a history of sexual abuse. The absence of either of these findings has an LR that is statistically less than 1.0, but the point estimate is so close to 1.0 that it lacks diagnostic utility.

Transections in the posterior hymen are consistent with genital trauma from sexual abuse with a positive LR of 3.1, but the presence of transections has a large CI so that the diagnostic impact is uncertain (95% CI, 0.13-76). The wide 95% CI is a reflection of the small number of children included in the study. The absence of a transection has little impact on the likelihood that a child has been abused (negative LR, 0.99; 95% CI, 0.98-1.0) (Table 3). While this LR data comes from only 1 study, 4 studies

Table 1. Accuracy Studies^a

Source	Study Quality ^b	No. of Participants	No. Abused	Age Range, y	Reference Standard
Berenson et al, ²⁸ 2002	3	386	189	3-8	Child protection team; History of sexual abuse was based on a clinic interview including administration of a nonvalidated 8-item scale (Digital/Genital Penetration Rating Scale); scale did not include physical examination findings as a measure
Berenson et al, ²⁹ 2000	3	392	192	3-8	Child protection team; History of sexual abuse was based on a clinic interview including administration of a nonvalidated 8-item scale (Digital/Genital Penetration Rating Scale); scale did not include physical examination findings as a measure

^aChildren specifically evaluated to determine physical examination findings related to a history of child sexual abuse.

^bSee Box 2 for explanation of study quality.

Table 2. Studies of Prepubertal Girls to Establish Normal Physical Examination Findings^a

Source	Study Quality ^b	No. of Participants	Age Range	Inclusion Criteria
Berenson and Grady, ³⁰ 2002	4	93	3-9 y	Separate parent and child interviews; parent interview included administration of structured questionnaire, Child Sexual Behavior Inventory
Heger et al, ³¹ 2002	4	147	Prepubertal	Separate parent and child interviews
Myhre et al, ³² 2003	4	195	5-6 y	Parent interview and physical examination findings
Berenson, ³³ 1995	4	134	Newborn-3 y	Parent interview and medical record review
Berenson, ³⁴ 1993	4	62	Newborn-1 y	Parent interview and medical record review
Berenson et al, ³⁵ 1992	4	202	Newborn-7 y	Parent interview and medical record review
Gardner, ³⁶ 1992	4	79	3 mo-11 y	Parent history by clinician
Berenson et al, ³⁷ 1991	4	468	Newborn	None; examinations conducted prior to discharge examination after delivery
McCann et al, ³⁸ 1990	4	93	Newborn-10 y	Parent history by clinician including administration of a structured interview to determine sexual abuse (possible physical, behavioral, or emotional symptoms); review of physical examination findings by physicians experienced in child sexual abuse examinations; and high incidence of other examination findings not used to determine normality

^aStudies that included only girls without a history of sexual abuse permitted for calculation of specificity of physical examination findings.

^bSee Box 2 for explanation of study quality.

Table 3. Accuracy of Signs for Genital Trauma Resulting From Sexual Abuse^a

	Sensitivity, % ^b	Specificity, % ^c	LR (95% CI)	
			Positive	Negative
Signs From Berenson et al²⁹				
Vulvar				
Ecchymosis	1	100	3.1 (0.13-76)	0.99 (0.98-1.0)
Laceration	1	100	3.1 (0.13-76)	0.99 (0.98-1.0)
Vaginal discharge ^d	11	96	2.7 (1.2-6.0)	0.93 (0.88-0.98)
Labial adhesion	13	93	1.8 (0.95-3.3)	0.94 (0.88-1.0)
Erythema	41	63	1.1 (0.87-1.4)	0.93 (0.8-1.1)
Linea vestibularis	7	93	1.0 (0.5-2.2)	1.0 (0.95-1.1)
Perineal depression	1	98	1.0 (0.26-4.1)	1.0 (0.97-1.03)
Friability	1	96	0.15 (0.02-1.2)	1.03 (1.0-1.06)
Prominent vessels in hymen	8	94	1.2 (0.59-2.5)	0.99 (0.93-1.0)
Superior/anterior hymen				
Tags	3	98	1.7 (0.42-7.2)	0.99 (0.96-1.0)
Superficial notch	3	98	1.3 (0.35-4.8)	0.99 (0.97-1.0)
Bumps	28	76	1.2 (0.84-1.6)	0.95 (0.84-1.1)
Longitudinal intravaginal ridge	79	27	1.1 (0.96-1.2)	0.79 (0.55-1.1)
Deep notch	1	100	1.0 (0.02-52)	1.0 (0.99-1.01)
External ridge	1	100	1.0 (0.02-52)	1.0 (0.99-1.01)
Periurethral bands	94	5	0.99 (0.94-1.0)	1.1 (0.51-2.5)
Vestibular bands	26	73	0.95 (0.68-1.3)	1.0 (0.91-1.1)
Inferior/posterior hymen				
Deep notch	1	100	5.2 (0.25-108)	0.99 (0.97-1.0)
Perforation	1	100	3.1 (0.13-76)	0.99 (0.98-1.0)
Transection	1	100	3.1 (0.13-76)	0.99 (0.98-1.0)
Superficial notch	4	98	1.8 (0.54-6.1)	0.98 (0.95-1.0)
External ridge	8	92	0.98 (0.50-1.9)	1.0 (0.95-1.1)
Bumps	31	66	0.92 (0.69-1.2)	1.0 (0.91-1.2)
Longitudinal intravaginal ridge	63	26	0.85 (0.74-0.97)	1.5 (1.1-2.0)
Tags	1	98	0.42 (0.08-2.1)	1.0 (0.99-1.02)
Signs From Berenson et al²⁸				
Difference in hymenal tissue width at 3 and 9 o'clock				
Supine position during examination, mm asymmetry				
≥1.5	7	94	1.35 (0.59-3.11)	0.98 (0.92-1.04)
≥0.5	54	50	1.1 (0.88-1.3)	0.91 (0.73-1.1)
≥1.0	19	81	1.0 (0.65-1.6)	1.0 (0.90-1.1)
Knee-chest position during examination, mm asymmetry				
≥1.5	7	97	2.5 (0.77-8.4)	0.95 (0.9-1.0)
≥0.5	54	51	1.1 (0.86-1.4)	0.9 (0.69-1.2)
≥1.0	17	90	1.7 (0.92-3.2)	0.92 (0.83-1.0)
Horizontal hymenal diameter >6.5 mm				
Supine position during examination				
	32	73	1.2 (0.85-1.6)	0.93 (0.81-1.1)
Knee-chest position during examination ^d				
	29	86	2.0 (1.3-3.2)	0.83 (0.74-0.93)
Amount of hymenal tissue <1.0 mm				
Supine position during examination				
6 o'clock	1	100	3.2 (0.13-78)	0.99 (0.98-1.0)
3 o'clock	1	99	2.2 (0.20-24)	0.99 (0.97-1.0)
9 o'clock	1	99	0.5 (0.05-5.5)	1.0 (0.99-1.1)
Knee-chest position during examination				
6 o'clock	2	100	7.4 (0.39-143)	0.98 (0.96-1.0)
3 o'clock	1	99	1.1 (0.16-7.6)	1.0 (0.97-1.01)
9 o'clock	3	100	11 (0.55-201)	0.97 (0.94-1.0)

Abbreviations: CI, confidence interval; LR, likelihood ratio.

^aValues were rounded to the nearest whole number percentage.^bSensitivity values less than 1% were rounded to 1%.^cSpecificity values greater than 99% were rounded to 100%.^dThe 95% CIs for both the positive and negative LRs do not include 1.0.

Table 4. Vulvar Findings in Nonabused Population

Finding	No. of Participants	Specificity, % (95% CI) ^a
Erythema		
Heger et al, ³¹ 2002	147	51 (43-59)
McCann et al, ³⁸ 1990	91	44 (34-54)
Labial adhesion		
Myhre et al, ³² 2003	195	92 (89-96)
Heger et al, ³¹ 2002	147	84 (78-90)
McCann et al, ³⁸ 1990	90	61 (51-71)
Linea vestibularis		
Myhre et al, ³² 2003	133	98 (95-100)
Heger et al, ³¹ 2002	147	81 (75-87)
Posterior fourchette		
Increased vascularity		
Gardner, ³⁶ 1992	79	85 (77-93)
Ragged		
Myhre et al, ³² 2003	195	97 (95-99)
Gardner, ³⁶ 1992	79	82 (74-91)
McCann et al, ³⁸ 1990	88	8 (95-100)
Urethral dilation		
Gardner, ³⁶ 1992	79	72 (62-82)
McCann et al, ³⁸ 1990	85	85 (77-92)
Vaginal discharge		
Myhre et al, ³² 2003	195	98 (97-100)
Gardner, ³⁶ 1992	79	95 (90-100)
McCann et al, ³⁸ 1990	76	97 (94-100)

Abbreviation: CI, confidence interval.

^aFrequency of findings in these studies that only involved nonabused children is equal to 1 minus specificity.**Table 5.** Hymenal Findings in Nonabused Population

Finding	No. of Participants	Specificity, % (95% CI or Range) ^a
Asymmetric hymen		
Gardner, ³⁶ 1992	79	91 (85-97)
Bumps or mounds		
Myhre et al, ³² 2003	175	77 (70-83)
Berenson and Grady, ³⁰ 2002 ^b	93	23-47 (37-58); (13-32); (20-43)
Heger et al, ³¹ 2002	147	66 (58-74)
Berenson, ³⁴ 1993	57	95 (89-100)
Berenson et al, ³⁵ 1992	202	93 (89-96)
Gardner, ³⁶ 1992	79	89 (82-96)
McCann et al, ³⁸ 1990	80	66 (67-86)
Erythema		
Myhre et al, ³² 2003	194	99 (98-100)
Heger et al, ³¹ 2002	147	51 (43-59)
External ridge		
Myhre et al, ³² 2003	175	98 (96-100)
Berenson and Grady, ³⁰ 2002 ^b	93	97-100 (93-100); (96-100); (98-100)
Berenson et al, ²⁸ 2002	468	13 (10-16)
Berenson, ³³ 1995	134	96 (92-99)
Berenson, ³⁴ 1993	57	86 (77-95)
Berenson et al, ³⁵ 1992	201	85 (80-90)
Large hymenal opening		
Myhre et al, ³² 2003	195	82 (76-87)
Heger et al, ³¹ 2002	147	69 (62-77)
Gardner, ³⁶ 1992	79	89 (82-96)
Longitudinal intravaginal ridge		
Berenson and Grady, ³⁰ 2002 ^b	93	8-14 (7-21); (3-17); (1-15)
Heger et al, ³¹ 2002	147	6 (2-10)
Berenson, ³³ 1995	134	40 (35-44)

(continued)

including only prepubertal girls without a history of genital trauma from sexual abuse report the specificity of transections based on their location within the hymen.

Deep notches of the posterior hymen are consistent with genital trauma from sexual abuse (positive LR of 5.2). Similar to transections, the small number of children in the study explains the wide 95% CIs, making the diagnostic impact uncertain (95% CI, 0.25-108). Additionally, the absence of a deep notch in the posterior hymen has little impact on the likelihood that a child has been abused (negative LR, 0.99; 95% CI, 0.97-1.0).

Perforations of the posterior hymen are associated with genital trauma from sexual abuse (positive LR, 3.1; 95% CI, 0.13-76). Like transections and deep notches, the diagnostic impact of this finding is unclear and the absence of this finding has limited utility in determining whether a child has been abused (negative LR, 0.99; 95% CI, 0.98-1.0).

TABLE 4, TABLE 5, TABLE 6, and TABLE 7 list the specificity of findings from the nonabused population. Vulvar findings are reported in Table 4. An infrequent finding in nonabused population is vaginal discharge ($\geq 95\%$ specificity in all studies); in other words, among girls who have not experienced sexual abuse, less than 5% have vaginal discharge.

Table 5 presents the specificity of hymenal findings in the nonabused population. Possibly because of the examiner's subjective interpretation, there is wide variation in the specificity of children with findings such as bumps, tags, and notches.

Table 6 and Table 7 summarize hymenal findings in the anterior or superior and posterior or inferior locations. It is difficult to comment on the specificity of these findings in the different locations because few of the studies permitted abstraction of data in this format. For example, only 1 study permitted calculation of the specificity of posterior and inferior superficial and deep notches. Four studies permitted for the calculation of specificity of transections; the specificity was 99% to 100%. Only 1 nonabused prepubertal girl among all 4 study

populations was noted to have a transection at 3 o'clock. There were no transections noted in the posterior hymen between 4 and 8 o'clock.

Limitations

This study has several significant limitations. First, most of the findings are uncommon in the nonacute population. Second, the test characteristics reported can only be applied to prepubertal girls with a nonacute history of sexual abuse. Third, many studies were excluded either because they lacked an acceptable reference standard or because they combined findings of prepubertal and postpubertal girls; therefore, the calculation of test characteristics was either not possible or was based on few participants. Test characteristics were based on the results of only 2 studies. Fourth, most eligible studies in this review included only prepubertal girls who were not sexually abused so that the sensitivity of findings was not determined. Fifth, the lack of standard definitions made it impossible to combine findings.

The large ranges in specificity for some findings may have resulted from the lack of standard definitions and examination techniques. For example, the specificity of hymenal notches ranged from 27% to 100%. Studies included defined ventral or anterior notches as either 12 o'clock in annular hymens³¹ or as a disruption of the hymenal membrane at 11 or 1 o'clock in crescent-shaped hymens.³⁸ Different examination techniques may be responsible for some of the variation. For example, if an examiner did not use labial traction he/she may not be able to visualize the entire hymen and therefore may not be able to accurately determine if there is a notch or bump. Additionally, if a child is only examined in the supine and not the knee-chest position, the findings may be missed or mischaracterized. For example, an examiner may be convinced they are seeing a notch of the posterior hymen in a child in the supine position while the examination in the knee-chest position demonstrates that the finding is more consistent with an interrupted portion of the hymen.

Table 5. Hymenal Findings in Nonabused Population (continued)

Finding	No. of Participants	Specificity, % (95% CI or Range) ^a
Longitudinal intravaginal ridge		
Berenson, ³⁴ 1993	57	47 (34-60)
Berenson et al, ³⁵ 1992	201	75 (69-81)
Berenson, ³⁷ 1991	468	44 (40-49)
McCann et al, ³⁸ 1990	51	10 (2-18)
Notches		
Berenson and Grady, ³⁰ 2002 ^b	93	89-93 (88-99); (85-97); (81-97)
Heger et al, ³¹ 2002 ^c	147	27-82 (20-34); (75-88)
Berenson, ³³ 1995	134	91 (86-96)
Berenson, ³⁴ 1993	57	77 (66-88)
Berenson et al, ³⁵ 1992	202	92 (88-96)
Gardner, ³⁶ 1992	79	97 (94-100)
Berenson, ³⁷ 1991	468	72 (68-76)
McCann et al, ³⁸ 1990	76	93 (91-100)
Periurethral bands		
Berenson and Grady, ³⁰ 2002 ^b	93	1-2 (0.1-1); (0.01-1); (0-5)
McCann et al, ³⁸ 1990	89	49 (39-60)
Prominent vessels		
Myhre et al, ³² 2003	194	82 (76-87)
Heger et al, ³¹ 2002	147	63 (55-70)
Gardner, ³⁶ 1992	79	63 (53-74)
McCann et al, ³⁸ 1990	68	69 (58-80)
Tags		
Myhre et al, ³² 2003	175	100 (99-100)
Heger et al, ³¹ 2002	147	97 (94-100)
Berenson and Grady, ³⁰ 2002 ^b	93	87-90 (80-94); (83-97); (83-98)
Berenson, ³³ 1995	134	93 (88-97)
Berenson, ³⁴ 1993	57	89 (82-97)
Berenson et al, ³⁵ 1992	201	97 (95-99)
Gardner, ³⁶ 1992	79	98 (95-100)
Berenson, ³⁷ 1991	468	87 (84-90)
McCann et al, ³⁸ 1990	82	76 (66-85)
Thickened hymen		
Heger et al, ³¹ 2002	147	54 (46-62)
McCann et al, ³⁸ 1990	80	46 (35-57)
Vestibular bands		
Berenson and Grady, ³⁰ 2002 ^b	93	36-54 (44-65); (26-47); (33-58)

Abbreviation: CI, confidence interval.

^aSome studies had repeat examinations so ranges are shown.

^bStudy includes repeat examinations on the same children at different age.

^cStudy includes discussion of anterior and posterior notches.

Table 6. Superior and Anterior Hymenal Findings in Nonabused Population

Finding	No. of Participants	Specificity, % (95% CI)
Bumps		
Berenson et al, ³⁵ 1992	202	93 (89-96)
Longitudinal intravaginal ridge		
Berenson, ³³ 1995	134	93 (88-97)
Berenson et al, ³⁵ 1992	202	98 (95-100)
Ventral or anterior notch		
Heger et al, ³¹ 2002	147	27 (20-34)
Berenson, ³³ 1995	134	96 (92-99)
Berenson et al, ³⁵ 1992	201	94 (90-97)
Berenson et al, ³⁷ 1991 ^a	468	76-99 (72-81); (99-100)
McCann et al, ³⁸ 1990	82	99 (96-100)
Tags		
Berenson, ³³ 1995	134	97 (94-100)
Berenson et al, ³⁵ 1992	202	99 (97-100)

Abbreviation: CI, confidence interval.

^aThis study includes repeat examinations on the same children at different age so ranges are shown.

Table 7. Inferior and Posterior Hymenal Findings in Nonabused Population

Finding	No. of Participants	Specificity, % (95% CI)
Bumps		
Berenson et al, ³⁵ 1992	202	96 (93-99)
Longitudinal intravaginal ridge		
Berenson, ³³ 1995	134	80 (73-87)
Berenson et al, ³⁵ 1992	202	92 (88-96)
Notch		
Heger et al, ³¹ 2002	147	82 (75-88)
Berenson, ³³ 1995	134	100 (99-100)
Berenson et al, ³⁵ 1992	202	100 (99-100)
Berenson et al, ³⁷ 1991 ^a	468	98-99 (99-100)
Deep notch		
Myhre et al, ³² 2003	175	100 (99-100)
Superficial notch		
Myhre et al, ³² 2003	175	100 (98-100)
Transection		
Myhre et al, ³² 2003	175	100 (99-100)
Berenson and Grady, ³⁰ 2002	93	100 (99-100)
Heger et al, ³¹ 2002	147	100 (99-100)
Berenson et al, ³⁵ 1992	202	99 (99-100)
Width (narrowed hymen)		
Heger et al, ³¹ 2002	147	78 (71-84)
Berenson et al, ³⁵ 1992	134	96 (93-99)

Abbreviation: CI, confidence interval.

^aThis study includes repeat examinations on the same children at different age so ranges are shown.

Take-Home Message

This study focused on the test characteristics of nonacute genital findings in prepubertal girls to assist in the diagnosis of sexual abuse. Findings are limited to 2 case-control studies that included both sexually abused and nonabused girls. Nine other studies included in the review only included nonabused prepubertal girls. The diagnostic utility of the presence or absence of genital findings on the probability of genital trauma or maltreatment requires an understanding of the pretest probability. While population surveys suggest a starting pretest probability of 1%, this estimate applies only to the population of children at large. Once a family member expresses concern for maltreatment, the probability of maltreatment likely increases much higher than the general population. No population data exist to estimate the probability once a parent expresses suspicion of maltreatment. Physicians who evaluate at-risk children must assess the probability of maltreatment and must perform an objective physical examination unbiased by their pretest probability.

We caution that the findings for the diameter of the hymenal opening may lack precision and therefore are not clinically useful. The ability to adequately measure the diameter of the hymenal opening is limited by a child's ability to relax. It also is limited by the examiner's technique and tools. The diameter of the hymenal opening may be measured from photographs or by using tools such as a tape measure or by a grid on the viewfinder of a colposcope. The diameter of the hymenal opening varies with a patient's weight, age, amount of traction applied, and by the amount of hymenal tissue present. Measuring the diameter of the hymenal opening is not easily replicated and therefore this finding is not useful for helping to determine whether a prepubertal girl has been sexually abused.

A transection of the posterior hymen between 4 and 8 o'clock in prepubertal girls suggests genital penetrating trauma; however, the presence of this finding is not confirmatory of sexual abuse. Posterior hymenal findings including transections between 4 and 8 o'clock, deep notches, and perforations were not seen in studies of

prepubertal girls without a history of genital trauma from sexual abuse included in this systematic review. Therefore, one can conclude that the posterior hymenal findings of transections, deep notches, and perforations are extremely infrequent findings among children without a history of genital trauma from sexual abuse or other means.

Current guidelines suggest deep notches are supportive of a disclosure of sexual abuse. Without a disclosure of sexual abuse, interpretation of deep notches is considered an indeterminate finding that may require further evaluation.^{15,16} While deep notches of the posterior hymen were not found in prepubertal girls without a history of sexual abuse, the finding also is uncommon among sexually abused children (positive LR, 5.2; 95% CI, 0.25-108). Similarly, while some authors list hymenal transections as indicating penetrating trauma to the hymen, the finding also has a wide 95% CI (positive LR, 3.1; 95% CI, 0.13-76).^{15,16} However, because the prevalence of posterior hymenal findings (between 4 and 8 o'clock) such as transections, deep notches, and perforations are near zero in nonabused prepubertal girls, the presence of these examination findings suggests genital trauma from sexual abuse. In the absence of known genital trauma from accidental means, the possibility for sexual abuse must be strongly considered. In a prepubertal girl with a posterior hymenal finding of a transection (between 4 and 8 o'clock), a deep notch (between 4 and 8 o'clock), or a perforation, a report to child protective services should be strongly considered. At a minimum, an examination by a child abuse specialist should occur to confirm these findings and to help provide a careful interpretation regarding the likelihood of sexual abuse.

While identifying trauma and infectious diseases is extremely important and may require specific treatment, it also is important to reassure a child and her family that she is healthy and that her genital examination is normal. A clinician's assurance of a genital exami-

nation without evidence of trauma, and hence normal findings helps begin a process of healing.

This review should not be interpreted to mean that the physical examination of a prepubertal girl with a suspicion of sexual abuse has limited value. This review did not focus on the test characteristics of acute findings nor the usefulness of testing for STIs when indicated.

Previous research has stated that the majority of girls who provide a history of sexual abuse will have a normal or unremarkable examination.³⁹ Therefore, the fact that a child has an unremarkable genital examination should not dispute a child's allegations and a careful investigation by child protective services and/or law enforcement should continue.

In summary, results of this review suggest the accuracy of most genital findings used in isolation to predict nonacute sexual abuse among prepubertal girls is poor. In addition, this review suggests that the presence of vaginal discharge in a prepubertal girl should raise the suspicion of sexual abuse. Other findings that support a suspicion of sexual abuse in a prepubertal girl include deep notches and transections in the posterior hymen between 4 and 8 o'clock as well as a perforation of the hymen. It is important to note that a perforation of the hymen is not a finding commonly discussed in the literature and is not part of what is typically used to assist in the interpretation of physical examination findings for children suspected of being sexually abused.¹⁶

Transections, deep notches, and perforations of the hymen as described above raise the suspicion of sexual abuse and therefore should trigger a thoughtful investigation by the appropriate agency (social services and/or law enforcement) for the possibility of sexual abuse. The rarity of these findings in the studies included limits the ability of transections, deep notches, and perforations to be used alone in the diagnosis of sexual abuse among prepubertal girls.

Research in this area continues to be challenging and likely accounts for why only 2 studies met criteria to provide data regarding diagnostic accuracy. Recruitment of nonsexually abused children for thorough genital examinations is difficult. The definition of a criterion standard for child sexual abuse is lacking given the context of providing a medical diagnosis that requires a forensic interpretation, and the veracity of information provided to the physician in arriving at a diagnosis. The department of social services or child protection services and court decisions of abuse can be influenced by the interpretation of physical examination findings. Additionally, it can be difficult to determine the type of abuse a child has experienced, whether it is fondling or hymenal penetration. However, despite these limitations it is important to try to further the field with larger studies with a strict reference standard and definitions; these studies should include both sexually abused and nonsexually abused girls. They also should include standardized definitions of findings, standardized examination techniques of children in the supine position as well as knee-chest position when possible, and a description of the type of abuse experienced. This review illustrates that more data are needed to determine the test characteristics of physical examination findings in prepubertal girls with a suspicion of sexual abuse.

Reporting Concerns to the Appropriate Agency

All physicians in the United States are required by state law to report suspected cases of child sexual abuse.⁶ To determine the level of suspicion a physician should use the history, physical examination, and laboratory evaluation together. In general, when there is a history of possible sexual abuse because a child has made a concerning statement, if there is a concerning finding, or if there is a presence of an STI that is suggestive of sexual transmission, a report should be made to the appropriate agency according to local guidelines.

SCENARIO RESOLUTION

Case 1

The finding of erythema on the labia minora is a nonspecific finding (positive LR of 1.1) and therefore does not assist with determining whether the child has been sexually abused or the type of sexual contact the child has experienced. The fact that the child has an unremarkable examination of the hymen also does not assist with determining if the child has been sexually abused or with determining if the child has experienced some form of penetration (negative LR of most findings approximates to 1.0). The objective findings do not support or refute the mother's suspicion. Because the patient is a verbal child, a formal interview should be conducted with the child in a controlled atmosphere by a trained expert or a report made to the appropriate authorities. In many areas, specialized centers exist that assist in comprehensive evaluations for suspected sexual abuse cases. The physician should be reminded that his/her role is to help with coordinating follow-up services for many of these cases and to stress the importance of a comprehensive interview of the child by a skilled examiner that focuses on the concern for sexual abuse.

Case 2

It is difficult to determine a history of sexual abuse in a child before he/she is verbal. Hymenal injury, especially a transection (positive LR for transection of 3.1), without any other known history of trauma supports a suspicion of sexual abuse. An evaluation for sexual abuse should be completed and an immediate referral to the appropriate agency should be made.

Author Contributions: Dr Berkoff had full access to all of the data in the study and takes responsibility for the integrity of the data and the accuracy of the data analysis.

Study concept and design: Berkoff, Makoroff, Thackeray, Shapiro, Runyan.

Acquisition of data: Berkoff, Zolotor, Makoroff, Thackeray.

Analysis and interpretation of data: Berkoff, Zolotor, Makoroff, Shapiro, Runyan.

Drafting of the manuscript: Berkoff, Zolotor.
Critical revision of the manuscript for important intellectual content: Berkoff, Zolotor, Makoroff, Thackeray, Shapiro, Runyan.
Statistical analysis: Berkoff, Zolotor.
Administrative, technical, or material support: Makoroff, Thackeray, Shapiro, Runyan.
Study supervision: Runyan.
Financial Disclosures: None reported.
Funding/Support: Dr Berkoff was supported in part by the Robert Wood Johnson Clinical Scholars Program.
Role of the Sponsor: The funding source had no role in the design and conduct of the study; collection, management, analysis, and interpretation of the data; and preparation, review, or approval of the manuscript.
Additional Contributions: We thank David Simel, MD, for his guidance and careful review of the manuscript as well as Janet Serwint, MD, and Philip V. Scribano, DO, for their thoughtful review of this article. None of the persons listed were compensated for their contribution.

REFERENCES

1. US Department of Health and Human Services, Administration on Children, Youth, and Families. *Child Maltreatment 2005*. Washington, DC: US Government Printing Office; 2007.
2. Theodore AD, Chang JJ, Runyan DK, Hunter WM, Bangdiwala SI, Agans R. Epidemiologic features of the physical and sexual maltreatment of children in the Carolinas. *Pediatrics*. 2005;115(3):e331-e337.
3. Gallup Poll Organization. *Disciplining Children in America: A Gallup Poll Report*. Princeton, NJ: Gallup Poll Organization; 1995.
4. Dube SR, Anda RF, Felitti VJ, Chapman DP, Williamson DF, Giles WH. Childhood abuse, household dysfunction, and the risk of attempted suicide throughout the life span: findings from the Adverse Childhood Experiences Study. *JAMA*. 2001;286(24):3089-3096.
5. Christian CW, Lavelle JM, De Jong AR, Loiselle J, Brenner L, Joffe M. Forensic evidence findings in prepubertal victims of sexual assault. *Pediatrics*. 2000;106(1 pt 1):100-104.
6. Kellogg N. The evaluation of sexual abuse in children. *Pediatrics*. 2005;116(2):506-512.
7. Adams JA. Normal studies are essential for objective medical evaluations of children who may have been sexually abused. *Acta Paediatr*. 2003;92(12):1378-1380.
8. Heger A, Ticson L, Velasquez O, Bernier R. Children referred for possible sexual abuse: medical findings in 2384 children. *Child Abuse Negl*. 2002;26(6-7):645-659.
9. McCann J, Voris J, Simon M. Genital injuries resulting from sexual abuse: a longitudinal study. *Pediatrics*. 1992;89(2):307-317.
10. McCann J, Voris J. Perianal injuries resulting from sexual abuse: a longitudinal study. *Pediatrics*. 1993;91(2):390-397.
11. McCann J, Miyamoto S, Boyle C, Rogers K. Healing of hymenal injuries in prepubertal and adolescent girls: a descriptive study. *Pediatrics*. 2007;119(5):e1094-e1106.
12. McCann J, Miyamoto S, Boyle C, Rogers K. Healing of nonhymenal genital injuries in prepubertal and adolescent girls: a descriptive study. *Pediatrics*. 2007;120(5):1000-1011.
13. Kellogg ND, Menard SW, Santos A. Genital anatomy in pregnant adolescents: "normal" does not mean "nothing happened." *Pediatrics*. 2004;113(1 pt 1):e67-e69.
14. Adams JA, Harper K, Knudson S, Revilla J. Examination findings in legally confirmed child sexual abuse: it's normal to be normal. *Pediatrics*. 1994;94(3):310-317.
15. Adams JA, Kaplan RA, Starling SP, et al. Guidelines for medical care of children who may have been sexually abused. *J Pediatr Adolesc Gynecol*. 2007;20(3):163-172.
16. Adams JA. Guidelines for medical care of children evaluated for suspected sexual abuse: an update for 2008. *Curr Opin Obstet Gynecol*. 2008;20(5):435-441.
17. Bernet W; American Academy of Child and Adolescent Psychiatry. Practice parameters for the forensic evaluation of children and adolescents who may have been physically or sexually abused. *J Am Acad Child Adolesc Psychiatry*. 1997;36(10)(suppl):375-565.
18. American Professional Society on the Abuse of Children. *Psychosocial Evaluation of Suspected Sexual Abuse in Children*. 2nd ed. Elmhurst, IL: American Professional Society on the Abuse of Children; 1997:1-8.
19. Child Medical Evaluation Program. North Carolina Child Medical Evaluation Program Tool. <http://www.med.unc.edu/cmep/forms/>. Accessed July 29, 2008.
20. Friedrich WN, Fisher JL, Dittner CA, et al. Child Sexual Behavior Inventory: normative, psychiatric, and sexual abuse comparisons. *Child Maltreat*. 2001;6(1):37-49.
21. Simms MD, Dubowitz H, Szilagyi MA. Health care needs of children in the foster care system. *Pediatrics*. 2000;106(4)(suppl):909-918.
22. De Jong AR. Impact of child sexual abuse medical examinations on the dependency and criminal systems. *Child Abuse Negl*. 1998;22(6):645-652.
23. Rosen DS. Physiologic growth and development during adolescence. *Pediatr Rev*. 2004;25(6):194-200.
24. McCann J, Voris J, Simon M, Wells R. Comparison of genital examination techniques in prepubertal girls. *Pediatrics*. 1990;85(2):182-187.
25. Makoroff KL, Brauley JL, Brandner AM, Myers PA, Shapiro RA. Genital examinations for alleged sexual abuse of prepubertal girls: findings by pediatric emergency medicine physicians compared with child abuse trained physicians. *Child Abuse Negl*. 2002;26(12):1235-1242.
26. Sinal SH, Lawless MR, Rainey DY, et al. Clinician agreement on physical findings in child sexual abuse cases. *Arch Pediatr Adolesc Med*. 1997;151(5):497-501.
27. Centers for Disease Control and Prevention. Sexually transmitted diseases treatment guidelines 2006. <http://www.cdc.gov/std/treatment/2006/sexual-assault.htm>. Accessed March 6, 2008.
28. Berenson AB, Chacko MR, Wiemann CM, Mishaw CO, Friedrich WN, Grady JJ. Use of hymenal measurements in the diagnosis of previous penetration. *Pediatrics*. 2002;109(2):228-235.
29. Berenson AB, Chacko MR, Wiemann CM, Mishaw CO, Friedrich WN, Grady JJ. A case-control study of anatomic changes resulting from sexual abuse. *Am J Obstet Gynecol*. 2000;182(4):820-831.
30. Berenson AB, Grady JJ. A longitudinal study of hymenal development from 3 to 9 years of age. *J Pediatr*. 2002;140(5):600-607.
31. Heger AH, Ticson L, Guerra L, et al. Appearance of the genitalia in girls selected for nonabuse: review of hymenal morphology and nonspecific findings. *J Pediatr Adolesc Gynecol*. 2002;15(1):27-35.
32. Myhre AK, Berntzen K, Bratlid D. Genital anatomy in non-abused preschool girls. *Acta Paediatr*. 2003;92(12):1453-1462.
33. Berenson AB. A longitudinal study of hymenal morphology in the first 3 years of life. *Pediatrics*. 1995;95(4):490-496.
34. Berenson AB. Appearance of the hymen at birth and one year of age: a longitudinal study. *Pediatrics*. 1993;91(4):820-825.
35. Berenson AB, Heger AH, Hayes JM, Bailey RK, Emans SJ. Appearance of the hymen in prepubertal girls. *Pediatrics*. 1992;89(3):387-394.
36. Gardner JJ. Descriptive study of genital variation in healthy, nonabused premenarchal girls. *J Pediatr*. 1992;120(2 pt 1):251-257.
37. Berenson A, Heger A, Andrews S. Appearance of the hymen in newborns. *Pediatrics*. 1991;87(4):458-465.
38. McCann J, Wells R, Simon M, Voris J. Genital findings in prepubertal girls selected for nonabuse: a descriptive study. *Pediatrics*. 1990;86(3):428-439.
39. Adams JA. Medical evaluation of suspected child sexual abuse. *J Pediatr Adolesc Gynecol*. 2004;17(3):191-197.